Transrectal ultrasound for swine reproduction management

The objective of this article is to describe the main uses of the transrectal ultrasound transducer for pigs, as well as the advantages of this technique for visualisation of reproductive anatomy and the benefits this technique can provide at farm level.

by L. Arévalo, F. Martínez, L. Gil, V. Luño.
Summarised by Yolanda Trillo,
IMV imaging.
www.imv-imaging.com

The reliability of pregnancy diagnosis is widely believed to be 97% with transabdominal scanning. However, increasingly, ultrasound is being used transrectally to evaluate the ovarian structures.

Ultrasound allows early detection of pregnancy, determination of litter size, detection of pathological problems in the reproductive tract as well as the study of ovaries, follicular development and the time of ovulation. It is also useful for decision making at key moments in the reproductive management of the animal, such as the onset of puberty or when alterations related to fertility are required.

To perform a thorough examination of the animal, it is necessary to appreciate subtle anatomical variations, which depend on age and reproductive status of the animal.

In sows, the prepubertal phase is around five months of age. At this time, the uterus is located at the level of the pelvic symphysis, caudal to the urinary bladder and far from the abdominal wall, so it is an area difficult to access transabdominally.

When the sow is more than five months old, increased ovarian activity leads to growth of the uterus, so that the two uterine horns move cranial to the urinary bladder. In multiparous sows, the uterus occupies an even larger volume, moving further cranially (to the level of the third or fourth lumbar vertebra).

In pregnant sows, the uterus can be found as far cranially as the last thoracic vertebra, with the horns in contact with the abdominal wall. The ovaries are consistently located around the level of the 6th lumbar vertebra in the dorsal abdominal cavity.

Fig. 1. Ovary ultrasound image with follicles > 10mm close to the time of ovulation.

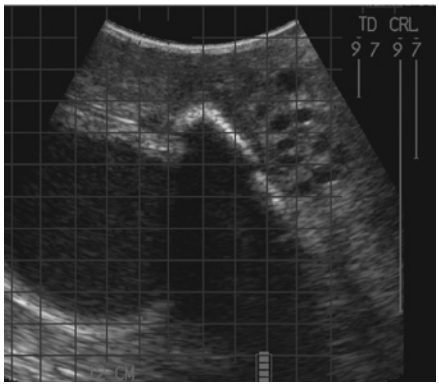

Technique

Transrectal ultrasound should be performed in a confined space where possible, to limit movement of the sow. Before scanning, faeces must be evacuated from the rectum to allow good contact with the rectal mucosa. The probe is protected with a flexible plastic adapter and placed in a glove lubricated with gel.

First, introduce a finger and then stimulate the area with rotating movements to relax the anal sphincter and thus allow easy introduction of the arm. Initially, the bladder will be identified, serving as an anatomical reference point. The bladder is identified ultrasonographically as a broad anechoic structure with a hyperechoic border. Subsequently, a sweeping motion is made with the probe along the rectal wall in a cranial direction. Both ovaries, uterine horns and the uterine body can be identified. Finally, the probe and arm are removed gently and both the equipment and the animal are cleaned to avoid genitourinary infections.

Monitoring follicular activity

At weaning, the sow's ovaries are usually small. By four days post-weaning, the follicles grow up to around 6mm in diameter, allowing estimation of the weaning-oestrus interval.

For comprehensive monitoring of follicular growth, it is necessary to scan the female once or twice daily from the point all follicles reach 6mm, and continue scanning until follicular structures are no longer detected. Due to the duration of ovulation, it is common to find preovulatory follicles larger than 10mm in size and haemorrhagic bodies from newly ovulated follicles concomitantly (Fig. 1).

Ovulation is considered complete when no preovulatory follicles are detected. It becomes impossible to visualise the ovary when haemorrhagic bodies predominate.

It has been shown that there are no diagnostic differences if ultrasound is performed every six or 12 hours after the detection of preovulatory follicles, taking no more than three or four minutes per female per scan.

Another advantage is the ability to check the presence of most of the corpora lutea and haemorrhagic bodies. Transrectal ultrasound allows more effective and complete visualisation of the echogenicity of these structures. Transabdominal ultrasound only allows visualisation of follicles larger than 7mm, making it impossible to determine the total number of growing follicles, the consistency of the ovarian structures or uterine content due to the low sensitivity of both the technique and the equipment used.

Between 50-80% of existing follicles and corpora lutea will not be detected by abdominal ultrasound.

Pregnancy checks

Transabdominal ultrasound for pregnancy diagnosis can be performed from day 21 post insemination by visualising the embryonic vessels and then repeated around day 28-30. Using transrectal ultrasound, we can perform earlier pregnancy diagnoses, around day 12-16 post-insemination.

Pregnancy diagnosis is made by visualisation of the corpus luteum, the presence of fluid in the uterine horns and changes in endometrial echogenicity. These

Continued on page 15

Continued from page 13
changes in endometrial echogenicity can only be determined by transrectal ultrasound.

Puberty/sexual maturity detection

The introduction of future breeding sows to a farm is a crucial stage for examination. If examination is not carried out, there may be economic repercussions from incorrect heat detection. When the first signs of heat are detected, the readiness to begin breeding can be estimated. However, silent heat occurrence in sexually mature sows is between 7-20%, therefore first ovulation is not always detected.

Transrectal ultrasound can indicate whether or not a female is mature enough to breed with around 97% reliability. In sexually immature sows the appearance of the uterus on ultrasound has a homogenous echotexture and it can be difficult to locate the uterine horns and ovaries. In sexually mature sows the uterine horns and ovaries are easily located ultrasonographically with the uterus appearing heterogenous.

These ultrasonographic changes can been seen between two and nine days before heat is observed in sows reaching sexual maturity.

Transrectal ultrasound is not superior to transabdominal ultrasound for the detection of puberty. However, it can provide more information because the reproductive organs are visualised more clearly, but also carries the risk of injury to the sow, due to smaller overall body size.

Fig. 2. Ovary ultrasound image with numerous ovarian cysts › 12mm.

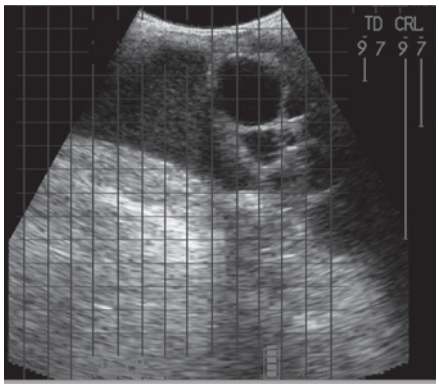

Reproductive failures

Reproductive failures can be due to various pathologies (ovarian or uterine) and these can be more easily identified using transrectal ultrasound. Ovarian cysts of follicular origin, from anovulatory follicles, or of luteal origin, originating from the abnormal development of a corpus luteum with trabecular structure, can be easily identified by a diameter greater than 12mm.

Transrectal ultrasound also enables counting of the total number of cystic structures, allowing diagnosis of polycystic ovaries, one of the most frequent reproductive pathologies in the porcine species (Fig. 2).

Another ovarian abnormality that can be identified is a failure of ovulation. This can be seen as the presence of medium sized follicles (7-9mm) in sows with signs of heat associated with lactations less than 16 days. We can also detect ovarian inactivity, characterised by the presence of several small follicles (‹6mm) with a long-lasting anoestrus, sometimes after lactation.

Paraovarian cysts, haematomas or tumours are other detectable pathologies associated with a total or partial failure of reproductive activity.

Changes at uterine level

Transrectal ultrasound allows examination of three criteria; the echogenicity of uterine fluid, the echotexture of the uterus and uterine horns, and the size of the uterus. The presence of any type of fluid is considered pathological unless it is due to the presence of semen, oestrus or a pregnancy. Fluid is otherwise indicative of exudative inflammation, likely endometritis, metritis or pyometra depending on the location and composition of the fluid. When assessing the uterine echotexture, we can visualise changes associated with the oestrus cycle or weaning. During oestrus and proestrus, the uterus is more heterogeneous, while after weaning it is more homogeneous (Fig. 3).

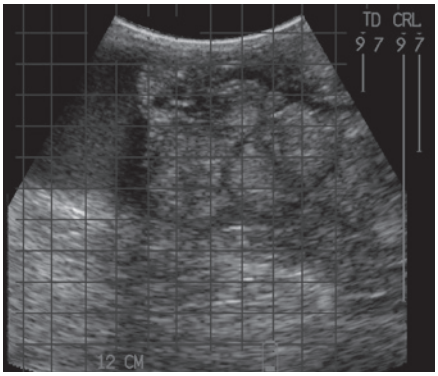

Fig. 3. Uterus ultrasound image during oestrus with signs of endometrial hypertrophy and oedema.

Conclusion

In conclusion, swine transrectal ultrasound is a simple and quick diagnostic method to perform at the farm level, although it does require ultrasonographer education and an animal of an adequate size. It allows the user to clearly visualise all the structures of the reproductive tract, monitor the follicular activity of the ovary, the presence of pathology and to perform earlier pregnancy diagnosis. This technique can become a complementary method to transabdominal ultrasound, which helps us to plan reproductive management, optimise artificial insemination protocols and reduce reproductive failures, improving the overall profitability of the farm. ■

References are available from the authors on request.
This study was conducted using the IMV imaging Easi-Scan Curve