

IBDV infection and immune suppression

by K. Schwarzer, INVE Nutri-Ad, Kloosterstraat 1, Bus 7, B-2460, Kasterlee, Belgium.

There are many factors causal to immune suppression which would lead to immune deficiency. One of the most significant factors is infectious bursal disease virus infection (IBDV) that causes severe immunosuppression of chickens. Immunosuppression caused by IBDV is of major interest because of the widespread occurrence of infection in commercial chickens.

Infection with IBDV at an early age significantly compromises the humoral and local immune responses of chickens. Until the emergence of the very virulent IBDV (vvIBDV) in 1986, the great economic losses resulted from the immunosuppressive effect of the virus. The appearance of highly pathogenic vvIBDV in Europe during 1988 increased the financial impact of the disease on producers.

These vvIBDV were reported to break through high levels of maternal antibodies in commercial flocks, causing up to 60-100% mortality rates in chickens and producing lesions typical of IBDV. In a recent study conducted by Abdel-Alim et al. (2003), seven Egyptian vvIBDV strains out of 24 samples examined have been identified by using RT-PCR-RFLP test.

A study at the Faculty of Veterinary Medicine, Cairo University, Veterinary Serum and Vaccine Research Institute Cairo, by Dr Awaad et al, was conducted in an attempt to counteract or modulate the immunosuppressive effect associated with infection with virulent IBDV (trial I), or vaccination with intermediate plus IBDV vaccine (trial II) in layer chickens by using two commercial immuno stimulants.

For estimation of the immune response, all groups were vaccinated with Newcastle disease virus (NDV) vaccines and bioassay study was carried out by NDV challenge.

Experimental design

Day old egg type male chickens were used in trial I and II. The viruses and vaccines included:

1 Virulent Infectious bursal disease virus (IBDV) strain. Bursal homogenate containing virulent Egyptian strain of IBDV that has

been characterised earlier by RT-PCR -RFLP was used in phase I.

1 Newcastle disease virus (NDV) challenge strain. A velogenic viscerotropic strain of Newcastle disease (VVND) characterised by Sheble and Reda (1976) was used in trial I and II.

1 NDV vaccines. Both live (B1 type, B1 strain) ND vaccine and Live (B1 type, La Sota strain) ND vaccine were used for vaccination of birds used in this study at 10 and 28 days of age respectively via eye-drop route. These vaccines were used in trial I and II.

1 IBDV vaccine. A freeze dried live vaccine Noblis Gumboro, grown on embryonated eggs was used in trial II.

Trial I: IBDV infection

Out of the 515 chicks used in this experiment 20 randomly collected were sacrificed and serum samples were collected for measuring the maternally acquired immunity (MAI) against NDV and IBDV.

A part of the chicks were equally selected into groups consisting of 55 birds each. Another part of birds were kept and at 27 days of age these birds were selected into two groups. At 27 days of age the birds of all groups, except one, as blank control group, were infected with IBDV.

For prophylactic study one group received feed treated at 1kg/ton with Immunoaid dry for the first three weeks of age. Another group of chicks were treated with Nutrilac IGA liquid via addition in drinking water at the dose of 3ml/litre for first five days and repeated at 15-17 days of age.

For therapeutic study another separate group of chickens was orally treated with Immunoaid dry in a dose of one kg/ton ration till the end of the experiment (42 days).

A further different group of chickens was treated with Nutrilac IGA liquid. Respectively in drinking water in a dose of 3ml/litre for five days after the appearance of the clinical manifestations of IBD (48 hours PI).

Chickens of all groups except one were vaccinated against ND at 10 and 28 days of age using Hitchner B1 and La-Sota vaccines by eye drop route respectively.

Trial II: IBDV vaccination

Similar set up of the trial as in Phase I but the chicks were vaccinated with 228E IBDV vaccine instead of infection.

Criteria for evaluation of the impact on immune suppression effects of the used products:

1 Immunoassay

To investigate the possible effect of the used immuomodulators on the humoral immunity before and after IBDV infection in trial I, serum samples were used for determining antibody titers against NDV using haemagglutination inhibition test (HI).

To investigate the possible effect of the used immunomodulators on the humoral immunity before and after IBDV vaccination in trial II, serum samples were used for determining antibody titers against NDV using (HI) test.

1 Bioassay

In phases I and II, chickens of all groups were challenged with VVNDV two weeks post La-Sota vaccination and kept under close observation for further three weeks for clinical signs, mortality and lesions.

1 Relative bursa of Fabricius weight/body weight ratios

Five chickens per group were sacrificed at seven and 14 days post IBDV infection in trial I or vaccination in trial II. The bursa/body weight ratios were calculated by the formula, organ weight in grams x 1000/total body weight in grams and then expressed as the arithmetic mean for each group of birds.

1 Histopathology

Bursas of Fabricius collected at seven and 14 days PI or PV with IBDV were fixed in 15% buffered formalin. Paraffin-embedded sections were stained with Haematoxylin and Eosin, and were scored for histopathological lesions.

Continued on page 23

Continued from page 21

Bursae were subjectively scored as 1 – no lesions, 2 – focal, mild cell necrosis or depletion, 3 – multi-focal, one third to half of the follicle show atrophy and 4 – diffuse atrophy of all the follicles.

In trial I, the pathological alterations in form of inflammatory signs represented by oedema and inflammatory cell infiltration in the stroma accompanied with congestion of bursal blood vessels and areas of haemorrhages were detected in bursae of Fabricius (BF) of infected groups.

Moreover; the lymphoid follicles appeared atrophied with presence of vacuoles and inflammatory cell infiltration within the follicles. However, no pathological alterations were detected in BF of non-infected, non-treated birds (control blank group) during the period of the experiment.

At seven days post infection (PI), BF of IBDV infected untreated control birds showed connective tissue proliferation in stroma with inflammatory cells infiltration.

The lymphoid follicles appeared atrophied with increase of vacuolation and cysts formation inside the follicles.

Less numbers of lymphocytes were detected in the lymphoid follicles of this group accompanied with hyperplasia of reticular cells in the germinal centre. BF of birds infected with IBDV and treated with immune modulators showed at seven days PI the same previous changes but the lesions were milder in severity.

Germinal centre changes

In contrary to hyperplasia of reticular cells, the germinal centre showed an increase in number of lymphoblast cells and mitotic figures especially in the treated groups.

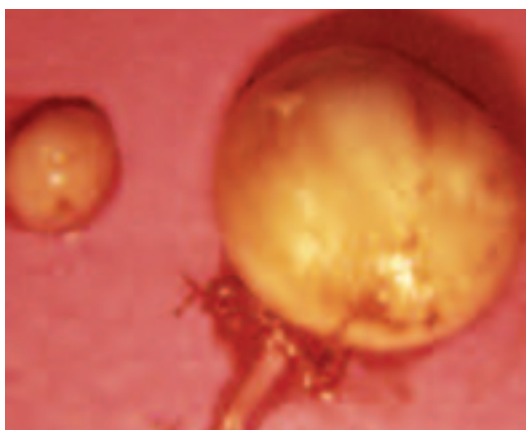
Days PI, the same pathological changes reported as at seven days PI were detected in infected untreated control group.

While there were a mild proliferation of fibrous connective tissue and few numbers of inflammatory cells in the stroma of BF of birds infected and treated with immune modulators.

Moreover, the lymphoid follicles increased in size, the germinal centre contained considerable numbers of lymphoblast cells with mitotic figures and lymphocytes began to appear in considerable numbers at periphery of the follicles.

In trial II, moderate pathological alterations in form of haemorrhage, oedema and inflammatory cells infiltration (specially heterophils and macrophages) in interstitial tissue, atrophied lymphoid follicles with vacuolation, few numbers of necrotic lymphocytes in the cortex, while the medulla showed large numbers of reticuloepithelial cells accompanied with reticular fibres in the germinal centre were observed at seven days PV of IBDV in BF of vaccinated untreated control birds.

In other treated groups, mild to moderate



Normal (left) and infected bursae of Fabricius.

pathological changes, which are less in severity as compared with their positive control group.

These mild lesions were inflammatory cells infiltration in stroma mainly heterophils and macrophages accompanied with oedema. The lymphoid follicles appeared smaller in size with presence of multiple vacuoles.

The germinal centre showed considerable numbers of lymphoblast cells and mitotic figures mixed with large numbers of reticuloepithelial cells and few numbers of macrophages. There were considerable numbers of mature lymphocytes in the cortex of lymphoid follicles.

Although the previous microscopical features were recorded in all treated groups it was milder in groups that were treated with Immunoaid dry and Nutrilac IGA (before and after IBD vaccination).

At 14 days PV of IBDV, BF of group seven showed heterophils infiltration in interstitial tissue which extend to the cortex of lymphoid follicles in addition to proliferation of fibrous connective tissue stroma.

The reticuloepithelial cells were replacing the germinal centre of lymphoid follicles with very few numbers of mitotic figures in addition to vacuolation. There were a few numbers of mature lymphocytes still present in the cortex.

Increased lymphocyte numbers

While those of treated groups there were signs of regeneration of lymphoid follicles represented by increase in number of lymphoblasts, lymphocytes and mitotic figures with decrease in numbers of reticuloepithelial cells in the germinal centre.

The numbers of mature lymphocytes began to increase in the cortex and follicles return to its normal size and appearance especially in groups treated with Immunoaid dry and Nutrilac IGA liquid.

Few cases showed proliferation of fibrous connective tissue in stroma and heterophils infiltration in lymphoid follicles.

Few cases revealed presence of reticular fibres in the germinal centre. No pathological alterations were detected in BF of IBDV unvaccinated, untreated birds (blank control groups)

during the period of the experiment.

The score of regenerating follicles 14 days PV ranged between 3.0-3.5 and 0.8-3.0 in prophylactic and therapeutic studies respectively as compared with 0 in the untreated control group respectively.

In this investigation, the immunosuppressive effect of IBDV infection or vaccination was evident as indicated by the significant lower bursal/body weight indices ($P < 0.05$) and histopathologic lesion score of infected and vaccinated groups when compared with that of the blank control groups.

In addition, the bioassay studies using VVNDV challenge proved the potency of NDV strain where infection resulted in 100% mortality in ND unvaccinated immune-compromised, untreated chicken groups (positive control).

Moreover, the efficacy of the used NDV vaccines well documented as the protection percentage reached 97.2 and 100% in blank vaccinated control groups.

Partial compensation

Generally speaking, from results of trial I and II it was observed that the two immune stimulants partially compensated the humoral immune suppression when used either before (prophylaxis) or after (therapy) IBDV infection or vaccination.

The prophylactic study showed a relatively higher protection percentage against VVND challenge in Immunoaid dry and Nutrilac IGA treated groups than their untreated controls. This confirms that both minimised the immune suppression resulted from either inoculation of virulent IBDV or intermediate plus IBDV vaccine.

The therapeutic use of these preparations revealed that only Immunoaid dry improved the protection percentage in immune compromised birds by field IBDV infection (83.8%) as compared with its positive control group (78.4%). This might be attributed to its constant administration in ration during the entire period of the trial.

The compensatory effect of all studied immune potentiators is confirmed histomorphologically by examination of BF.

Different degrees of regeneration in damaged lymphoid follicles was observed 14 days post IBDV infection or vaccination in all treated groups, however, Nutrilac IGA relatively gave the best regeneration score.

The present findings proved that the used immune potentiators are not only a compelling immune stimulators but also counterattacking modulators that accomplish immune-stimulation and compensate immune suppression.

These immune stimulating compounds could undoubtedly help in facing IBDV antigenic exposure and its immunosuppressive effect which is a hazard anticipating causative agent of serious economic impacts in poultry industry all over the world especially when given prophylactic.

n