

The worldwide importance of *Riemerella* infection in ducks

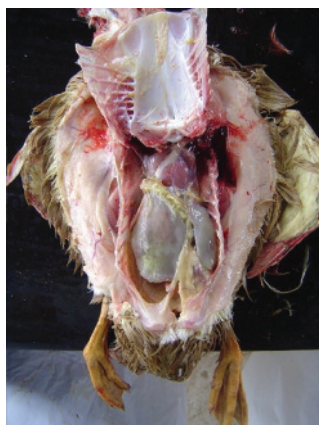Riemer first described an epizootic septicaemia of domestic fowl in 1904 and *Riemerella anatipestifer* infection, which is also known as new duck disease, duck septicaemia or infectious serositis, is a septicaemic disease of growing ducks that has worldwide importance.

by Sara Perez, Poultry Specialist Team, Minster Poultry Practice. Consultants for Cherry Valley Farms Ltd, UK. www.cherryvalley.co.uk

Over the years, *Riemerella anatipestifer* has been known by different names and this has led to confusion surrounding the incidence and treatment of the Riemerellosis. The bacterium shares phenotypic characteristics with *Flavobacter* spp. and has been historically and incorrectly known as *Moraxella anatipestifer* and *Pasteurella anatipestifer* due to their similar ecology and morphological/cultural characteristics. Its current classification as *Riemerella anatipestifer* was established by Segers and his colleagues, working in Belgium in 1993.

Riemerellosis normally affects ducklings aged between 2-6 weeks and sometimes up to eight weeks of age. The bacterium is most com-

Typical *Riemerella anatipestifer* septicaemia.



monly transmitted by hatching eggs, but there may be lateral spread through the respiratory route.

Outbreaks of the disease that lead to mortality are usually related to poor husbandry or environmental stress, for example; moving the birds from one farm to another or a breakdown in the ventilation equipment. Exposure to *Riemerella* does not normally lead to clinical disease in unstressed birds, but mortality can exceed 70% in severe cases.

Signs and symptoms may appear three days after a stressful event and in some cases, the first sign will be a spike in mortality from an apparently healthy flock.

Chronic symptoms include nervous signs like head shaking, walking with the head drawn into the body and difficulty walking. Affected ducks may be found on their backs, unable to right themselves.

Riemerellosis is a bacterial septicaemia and the lesions in affected birds may resemble streptococcus or *E. coli* infections. Congested lungs, an enlarged and pinkish liver, and an enlarged and purple spleen are typical lesions of the acute form of the disease.

In such cases, the vent may be stained a greenish colour and the beak may be congested, but the carcase is often well fleshed. In its less-acute or chronic form the disease commonly causes sinusitis and may result in pericarditis, perihepatitis and airsacculitis, particularly in the abdominal airsacs. As the disease progresses the posterior airsacs may become involved and females may suffer salpingitis.

In addition to this generalised septicaemia, Riemerellosis may be associated with thickening of the skin, especially of the ventral abdomen. Barely noticeable tracks of caseous pus can be found between the skin and the muscles, but it is unusual to find significant cellulitis.

The infection normally gets complicated with other secondary pathogens, such as *E. coli*. Therefore, in routine cultures the overgrowth of *E. coli* can make the isolation and identification of *Riemerella* difficult.

To confirm a diagnosis it is necessary to culture tissue samples taken from the brain or heart where it is unlikely to find *E. coli*.

Riemerella anatipestifer will grow on blood enriched agar, but the plates must be incubated at 37°C for at least 48 hours and sometimes up to 72 hours is needed before the small, greyish colonies become visible. Increasing the CO₂ level to 5% will encourage growth and aid identification. 15 serotypes of *Riemerella anatipestifer* have been identified that vary considerably in morphology and pathogenicity, but there are thought to be many and various field strains.

Other diseases that may cause similar signs in ducklings that should be considered as differential diagnoses include; *E. coli* and *Streptococcal* septicaemia, duck viral hepatitis, duck viral enteritis, coccidiosis and mycotoxicosis.

Riemerellosis can be very successfully treated by individual intramuscular antibiotic injection, but such treatment is very expensive to administer and not feasible in large flocks.


Treating commercial flocks

Commercial flocks can be treated with antibiotic in the drinking water (sulphadimidine at 30-60g/100 birds/day for three days) or in the feed (sulphaquinolone at 250-350ppm for five days), but prevention is better than cure.

Vaccination against Riemerellosis is possible using live sprayed or killed injectable products.

Standardised vaccines are available, but they rely on reference strains of *Riemerella anatipestifer* and may not give good protection in all situations. Best practice is to produce a vaccine using local isolates (autogenous vaccines), however *Riemerella anatipestifer* is not easy to culture and it will take time and patience to develop a formulation that works.

The key to controlling the disease without the cost or inconvenience of treating the flock is to manage it



properly and avoid stressing the ducks. If it is necessary to move the birds to different accommodation, they must be properly acclimatised beforehand.

Ducks that are kept at a low stocking rate and in good environmental conditions are less susceptible to the disease. Farms that are isolated, properly cleaned and practice all-in-all-out management have a low incidence of disease.

By following the principles above, Riemerellosis has not been diagnosed on Cherry Valley's farms in the UK for a number of years. Key elements in the disease control strategy include:

- Effective egg washing to control spread of the disease through the egg route and prevent vertical transmission.
- All-in-all-out flock placement and high standards of cleaning and disinfection to control horizontal spread between succeeding flocks.
- Duck friendly management, including appropriate stocking density and high standards of environmental control, to minimise stress on the animals.
- Regular veterinary visits, to assess the health status of the flock. ■

Riemerella anatipestifer cultured on Blood Agar.

