

# The latest thinking on Marek's disease in commercial poultry flocks

by Dr Francesco Prandini, DVM, Avian Technical Manager, Merial Europe, Middle East and Africa.

Marek's disease (MD) is a common lymphoproliferative disease affecting chicken health worldwide, usually characterised by mononuclear cellular infiltrates in peripheral nerves and various other organs and tissues including the skin.

It was once a devastating disease that decimated chicken flocks and, in the absence of control measures, is capable of causing devastating losses in commercial poultry flocks.

The disease is induced by an alpha-herpesvirus, Marek's disease virus or MDV, first isolated in 1968, and can be distinguished etiologically from other lymphoid neoplasms of birds.

MDV is cell-associated and includes three serotypes which are now grouped as the three species Gallid herpesvirus 2 (serotype 1), Gallid herpesvirus 3 (serotype 2) and Meleagrid herpesvirus 1 (serotype 3).

The different serotypes have major differences not only in the genome but also in the biological features. Serotype 1 MDV includes all the oncogenic strains and their attenuated forms; serotype 2 are non-oncogenic viruses isolated in chickens; and serotype 3 are non-oncogenic viruses isolated in turkeys, generally known as herpesvirus of turkeys or HVT.

On the basis of their virulence, serotype 1 strains have been further divided into patho-

## Fowl paralysis.



types, which are often referred to as mild (m)MDV, virulent (v)MDV, very virulent (vv)MDV, and very virulent plus (vv+)MDV strains, reflecting a continuous evolution of the virus from less severe forms reported by Josef Marek more than a century ago toward an increasing pathogenicity with mortality rates approaching 100% following exposure of unvaccinated chickens to (vv+)MDV.

Currently, MD is well under control in most parts of the world. Outbreaks still occur but MDV isolates of higher virulence than vv+ have not been reported. It is uncertain if MDV will continue its evolution towards greater virulence.

## Epidemiology & pathogenesis

The virus is almost everywhere, especially in large-scale chicken populations, and it has many factors working in its favour: it moves very easily from one bird to another, and the high-density living conditions of commercial chickens create an optimal environment for disease spread.

Even if a chicken is immunised, it will become a carrier, and once a chicken is infected, it will continue to harbour and potentially shed the virus for the rest of its life. As early as two weeks after inoculation or exposure, MDV is shed in the feather dust and can remain infectious in a poultry house for months or years depending on environmental conditions, and spread to other chickens.

As a result of continual shedding and virus stability in the poultry houses, it is assumed that most poultry houses are contaminated by infectious virus, thus chickens raised in commercial farms are probably exposed to MDV repeatedly and continuously over their lifetime. All chickens are susceptible to a variable degree to infection with MDV.

The natural route of MDV infection is through the lungs following inhalation of infectious cell-free MDV present in dander shed from feather follicles of infected chickens.

The role of the lung in MD pathogenesis is not clear and it is presumed that phagocytes present in the lung pick up the virus and carry it to lymphoid organs such as bursa of

Fabricius, thymus and spleen. MDV reaches the lymphoid organs within 2-3 days after infection.

A productive, cytolytic infection is shortly established in the lymphocytes of lymphoid organs, and is particularly evident between 5-6 days post-infection. The initial target cells for the cytolytic infection are B lymphocytes, followed by activation of numerous macrophages, T and B lymphocytes and some heterophils.

Infection becomes latent in T cells detectable not only in lymphoid organs but also in peripheral blood lymphocytes which probably are the disseminators of MDV to other tissues of the chickens.

A second wave of cytolytic infection is detected in most tissues of epithelial origin by the end of the second week after infection.

Productive infection with cell-free virus within the feather follicle epithelium is particularly important in transmission of MDV and will continue throughout the life of the infected chicken. In susceptible birds, reactivation of the virus from latency occurs, leading to transformation of CD4+ T cells with infiltration in various tissues and MDV-induced lymphomas which may develop in nerves, brain, skin, and any visceral organ.

MDV oncoprotein MEQ is clearly the major oncogene but other genes contribute to the oncogenicity.

## Clinical disease & pathology

MD consists of several distinct pathologic syndromes with lymphoproliferative syndromes being the most frequent and having the most practical importance. Of these, MD lymphoma is the most common, however fowl paralysis, skin leukosis and ocular lesions are additional clinical manifestations that have lymphoproliferative components; whereas non-neoplastic brain pathology is responsible for transient paralysis.

The incubation period can be short for several non-lymphomatous syndromes such as atrophy of the thymus and bursa of Fabricius which occurs within 6-8 days post infection. Transient paralysis usually occurs from 8-18 days post infection.

*Continued on page 13*

Continued from page 11

Under field conditions serious MD outbreaks begin at 8-9 weeks of age but also sometimes well after the onset of egg production. It is uncertain whether late onset of disease is caused by early or late infection.

MD signs vary according to the specific syndrome.

Chickens with MD lymphomas or fowl paralysis syndromes may exhibit signs such as weight loss, paleness, anorexia and become depressed and comatose prior to death, but few are specific to MD.

A particularly characteristic clinical presentation of unilateral paresis or spastic paralysis of a leg is a bird with one leg stretched forward and the other back.

One of the effects of MDV infections is immune suppression which is more severe with highly virulent MDVs; however, its mechanism is not well understood.

Pathologic changes consist mainly of enlarged nerves, skin nodular lesions (the most important cause of condemnation in broiler chickens), gross ocular changes and visceral lymphomas in multiple organs such as the liver, spleen, kidneys, gonads, proventriculus, etc, often associated with mortality.

In egg-type chickens mortality was much higher prior to the use of vaccines, frequently reaching 25-30% and occasionally rates approaching 100%.

However, some flocks experience significant disease outbreaks despite vaccination. Broiler flocks may experience some mortality and variable condemnation rates (mainly depending on duration of their production life).

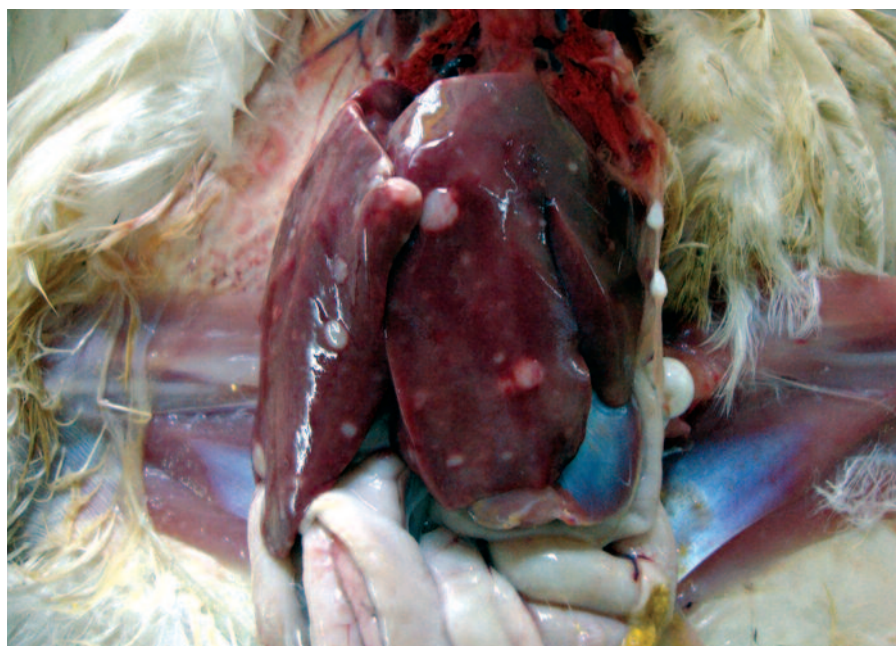
Several factors can influence mortality and severity of lesions: virulence of MDV strains, virus dose, route of exposure, host gender (with higher losses in females), maternal antibody (reducing and delaying MD mortality), host genetics, age at exposure (with less severe consequences in birds exposed later), environmental factors, concurrent immunosuppressive infections and stress conditions.

## Diagnostic methods

The principal methods to identify the presence of infection are isolation of the virus and demonstration of viral DNA in tissues. MDV can be isolated a few days after contact exposure and throughout the life of the chicken. Inocula may consist of blood lymphocytes, whole blood, splenocytes or tumor cells.

Polymerase Chain Reaction (PCR) assays using various primer sequences have recently been used to assay viral load in tissues from infected chickens and are becoming essential tools for diagnosis and epidemiological studies of MD, with the possibility of a rapid differential diagnosis of pathogenic and CVI988 vaccine strains using materials such as blood or feather tips.

Serotype-specific quantitative PCR tests



**Lymphomas in the liver.**

can also be used to monitor MD vaccination in blood or spleen samples, and for monitoring MDV serotype 1 in dust collected from poultry houses.

## Vaccines and vaccination

MD presents the best example for control of an oncogenic virus by mass vaccination using commercial vaccines.

Several different types of cell-associated MD vaccines are in common use, both individually and in various combinations. The most widely used products are low pathogenic serotype 1 MDV, particularly the CVI988 (Rispens) strain, naturally avirulent HVT, and serotype 2 viruses. The serotype 2 strains (such as SB-1 strain) are usually combined with HVT to take advantage of the synergistic activity documented between serotype 2 and 3.

All vaccine types are protective but to varying degree, and CVI988 vaccine appears to be the most effective one. Revaccination, by administering MD vaccines a second time, has been proven to be useful against MD in commercial poultry flocks.

The rationale is largely anecdotal, however the benefits of revaccination have been reproduced under laboratory conditions. MD vaccines are administered subcutaneously or intramuscularly to newly hatched chicks or in ovo between 18 and 19 days of embryonation. Early immunity is essential since most chicks face challenge from MDV within a few days of being introduced into brooding pens.

Serotype 3 strain replicates better in ovo than viruses of other serotypes. However, strain CVI988 has been shown to induce higher protection against challenge during the first three days of life when administered in ovo than at hatch.

The mechanisms of induction of protec-

tion by MD vaccines are not well understood. They appear to generate responses specifically directed against both the virus and the tumour. Presently, all breeders and commercial egg type chickens are vaccinated against MD, whereas broiler flocks are vaccinated in some but not all countries.

Although vaccination has been successfully used to prevent disease and tumour development, the vaccines do not prevent infection and transmission of the virulent virus.

## The future

The major concern of the poultry industry is the continuing evolution of virulence and emergence of more virulent MDV pathotypes that can break through the protective efficacy of the CVI988 vaccines.

Clearly there is a need for improved vaccines but a better understanding of MDV-induced transformation of infected cells and of the mechanisms of protection induced by MD vaccines is also important. The major effort in the immediate future will be towards the development of new generations of vaccines that can stop the evolutionary trend of MDV. It is very likely that recombinant DNA vaccines will be the basis for control of MDV in the future, by exploiting a combination of viral genes to be expressed (or deleted) to eventually exceed the efficacy of CVI988 strain.

Further studies taking advantage of the technological advances to unravel the major molecular pathways in MDV biology and pathogenesis can provide opportunities to develop alternative intervention strategies.

Exploitation of the findings from studies on genetic resistance in the fight against MD in commercial flocks will be a major focus in the coming years, as more and more data on genetic variations between resistant and susceptible lines begin to emerge. ■